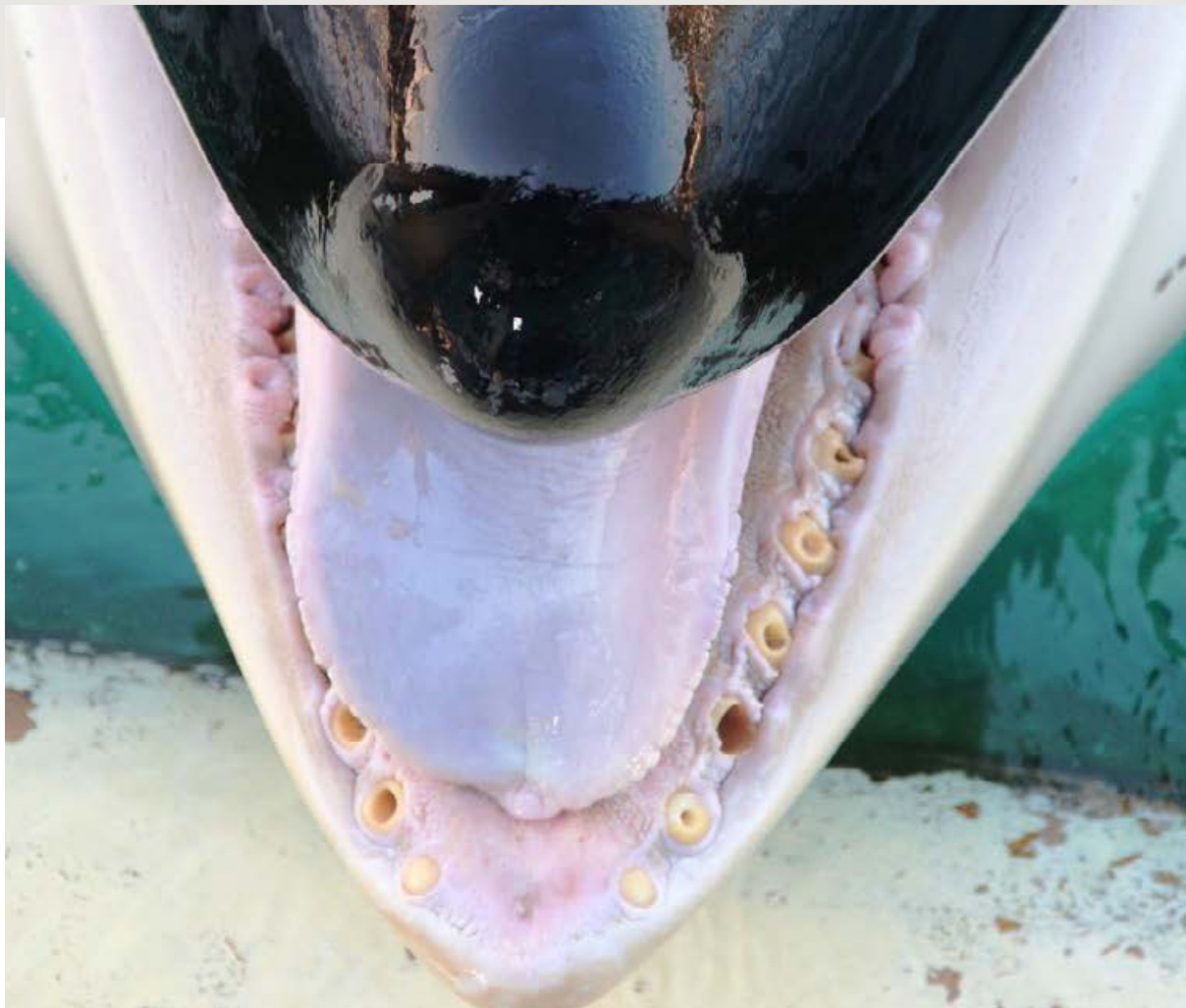

Expert report, March 2019

////////////////

INOUK

CAPTIVE 20-YEAR-OLD MALE ORCA,
WITH CHRONIC AND EXTENSIVE TOOTH DAMAGE



*Inouk's lower teeth in 2011, showing extensive dental damage, with teeth worn to the gums as well as drilled and broken teeth.
Photo: supplied to Orca Research Trust via Orca Aware.*

Report prepared for OneVoice by Ingrid N. Visser (PhD),
John Jett (PhD), Jeff Ventre (MD)

CONTENTS

Executive Summary	p. 3
Background	p. 4
Orca teeth	p. 5
Inouk's Tooth Damage	p. 12
Inouks Compromised Health	p. 17
References	p. 22
Appendix 1	p. 24
Appendix 2	p. 25

All photos Photo © Ingrid N. Visser, unless otherwise stated.

How to Cite: Visser, Ingrid N; Jett, John; Ventre, Jeff (2019). INOUK – Captive 20-year-old male orca, with chronic and extensive tooth damage. Report prepared for OneVoice (www.one-voice.fr) March 2019. Pp28.



Head office

BP 41 - 67065 Strasbourg Cedex
Tel : 03 88 35 67 30

Administrative and missions department

7 place de la République - CS 20263 - 56007 Vannes Cedex
Tel : 02 97 13 11 10
info@one-voice.fr www.one-voice.fr

Follow our news:     

EXECUTIVE SUMMARY

Inouk is a 20-year-old captive-born male orca with severely damaged teeth. Evidence of this damage is widespread in photographs, videos, direct observations made by the public. Documentation by Marineland Antibes, France, where he is held, supports this evidence.

As authors of one of the few scientific articles addressing captive cetacean oral biology, we have been requested to comment on the topic of teeth problems experienced by captive orca, the extent of the problem for Inouk, the consequences of diseased teeth, the origins of the problem and the treatments Inouk may be receiving.

In general, dental pathology is a direct, tragic, and widespread health consequence of orcas living in captive environments. Teeth are damaged by grinding on hard surfaces such as toys or concrete tank walls and fractured when the structural integrity is compromised and/or when whales bite down on steel gates in acts of aggression. The problem is ubiquitous for orca held in concrete tanks and is exacerbated by extremely bored whales living in small enclosures.

Teeth grinding is known as an oral "stereotypy" and is the equivalent of horses "cribbing" on their stalls. At marine parks like Marineland Antibes, France, the orcas have little mental stimulation and this leads to boredom and social strife.

Additionally, these large whales have nowhere to escape to when tensions are high and aggression occurs.

Dental pathology can be deadly in whales. In humans it is known to cause cardiovascular, kidney and lung disease. Bacteria from infected teeth and gums can and does travel to the lungs via the bloodstream in humans & other mammals. Those holding orca in captivity know this and workers regularly examine captive orca teeth and veterinarians place the whales on long-term antibiotics. Theme park trainers can be seen flushing bacteria, fish particles and other debris from the whales' broken teeth two to three times a day. Most theme parks describe this as 'superior dental care'.

Although it is not currently possible for those of us outside the captive industry to prove how infected-teeth leads to mortality in theme park orca; in all likelihood, the diseased teeth, with the associated over-utilization of antibiotics and immunosuppression is the number one cause of mortality in captive orca.

Over the next pages we present the case of Inouk in relation to other captive orca. We found that he has the highest-ranked damage for any orca currently documented by us. Documents from Marineland Antibes confirm his high dental damage and his behavioural problems.

BACKGROUND:

Inouk is a male orca (killer whale, *Orcinus orca*) born in captivity at Marineland Antibes, France, on 23 February 1999. Both his parents were wild-caught Icelandic orca - his mother (Sharkane) was captured in October 1989 when she was approximately 4 years old, and his father (Kim 2) was captured from the wild in October 1982, when he was approximately 1 year old. Both parents are dead.

Inouk has remained at Marineland Antibes his entire life and as of March 2019, he was held captive with three other orca; his sister Wikie (born in 2001) and his two nephews Moana (born 2011) and Keijo (born 2013). The latter is an inbred calf, as Keijo's mother (Wikie) and father (Valentin) are half siblings.

The concrete tank system that Inouk is held in (Figure 1), along with the other orca at Marineland Antibes, is comprised of a show tank (semicircle below with covered stadium on arch side) and three smaller 'back' tanks, with a medical tank (small square tank on right) which has a bottom that can be raised. Although the show tank is the largest tank, it is only 30m across at the widest point and only 11m deep (Appendix I). Inouk is estimated to be >5m long, therefore he can only swim five body lengths in a straight line and dive one body length, beyond his own size.




Figure 1. Concrete orca tank system, Marineland Antibes, France. The orca perform in shows in the semi-circular tank and are moved between the tanks depending on the schedule the workers set. Image: Google Earth (see Appendix I for schematic and dimensions)

ORCA TEETH:

Orca have homodont dentition, i.e., all the teeth are similar in shape. They are also monophyodont (they have one set of teeth during their lifespan). We use the notations of UL and UR to indicate Upper Left and Upper Right jaw/teeth and LL and LR to indicate Lower Left and Lower Right jaw/teeth. Each tooth is identified from the anterior of the animals' mouth to the posterior (Figure 2). Orca typically have 10 to 12 (occasionally up to 14) teeth¹, in each of the quadrants of their mouth, for a total of 40-56 teeth. Typically, the upper and lower teeth interlock when the mouth is closed. In an adult orca the teeth typically range up to 10 cm in length, or occasionally up to 13 cm.²

When *in situ*, the teeth are imbedded in the alveoli (tooth sockets with bone between the teeth, Figure 3). They are imbedded to just below the cingulum (also sometimes termed the 'neck' or 'collar', Figures 4 and 5) of the tooth, which is the zone of the tooth where the gum, in a healthy orca, would typically be present. This zone is also the transition area between the enamel and the cementum, which may show plaque, scale or calcification (calculus) deposits (Figures 4, 5 & 6).

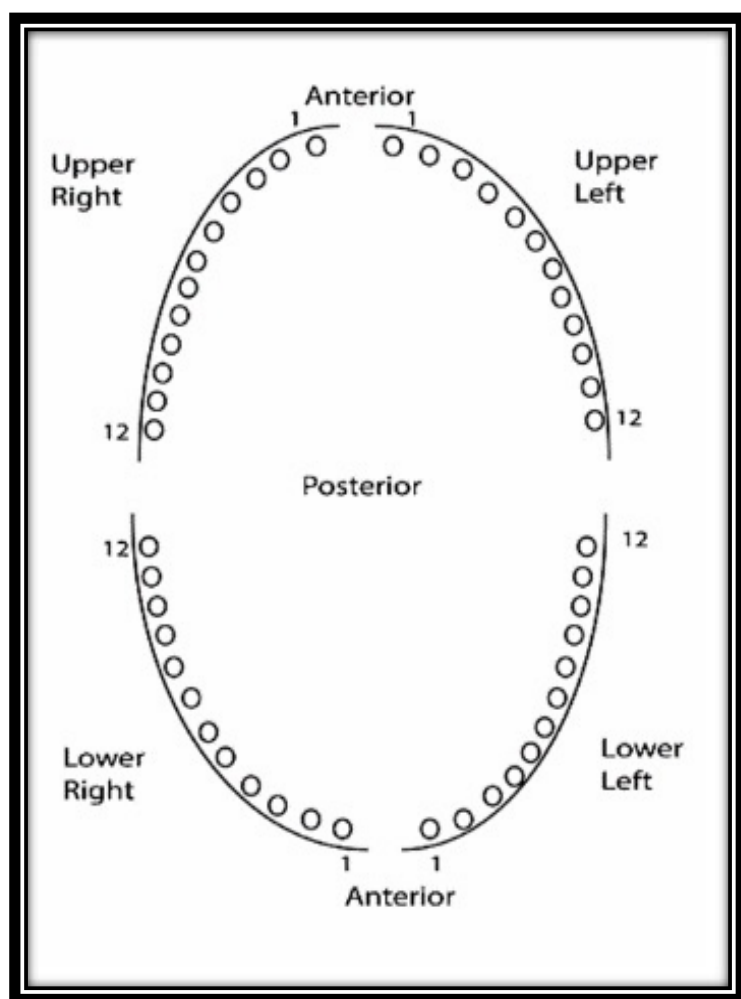


Figure 2. A simplified dental chart of orca teeth, where the dental configuration in this case is 12 teeth per quadrant³ (although orca may have up to 14 teeth per quadrant). From Jett, J., I. N. Visser, J. Ventre, J. Waltz and C. Loch (2017). "Tooth damage in captive orcas (*Orcinus orca*).³" *Archives of Oral Biology* 84: 151-160.

- ¹ The following authors give the range of orca teeth as 12-14 per quadrant. Eschricht DF. 1866. On the species of the genus *Orca* inhabiting the northern seas. In: Flower WH, editor. *Recent memoirs on the Cetacea*. London: Ray Society; p. 153-188, Scammon CM. 1874. *The marine mammals of the Northwestern coast of North America, together with an account of the American whale-fishery*. New York: G. P. Putnam's Sons, Glass BP. 1974. *A key to skulls of North American mammals*. Stillwater: Oklahoma State University, Heyning JE, Dahlheim ME. 1988. *Orcinus orca*. *Mammalian Species*. 304:1-9, Dahlheim ME, Heyning JE. 1999. Chapter 11, Killer whale *Orcinus orca* (Linnaeus, 1758). In: Ridgway SH, Harrison RJ, editors. *Handbook of Marine Mammals*. London: Academic Press; p. 281-322.
- ² Nishiwaki M. 1972. *General Biology*. In: Ridgway SH, editor. *Mammals of the Sea: Biology and Medicine*. Springfield, Illinois: Charles C Thomas; p. 3-204, Ford JKB. 2009. Killer whale. *Orcinus orca*. In: Perrin WF, Würsig B, Thewissen JGM, editors. *Encyclopedia of marine mammals*. San Diego: Academic Press; p. 650-657.
- ³ Kertesz (1993) stated that orca may have up to 15 teeth, but give no source (page 216 in; Kertesz P. 1993. *A colour atlas of veterinary dentistry and oral surgery* London, England: Wolfe Publishing.). See Footnote #2 for references for up to 14 teeth.

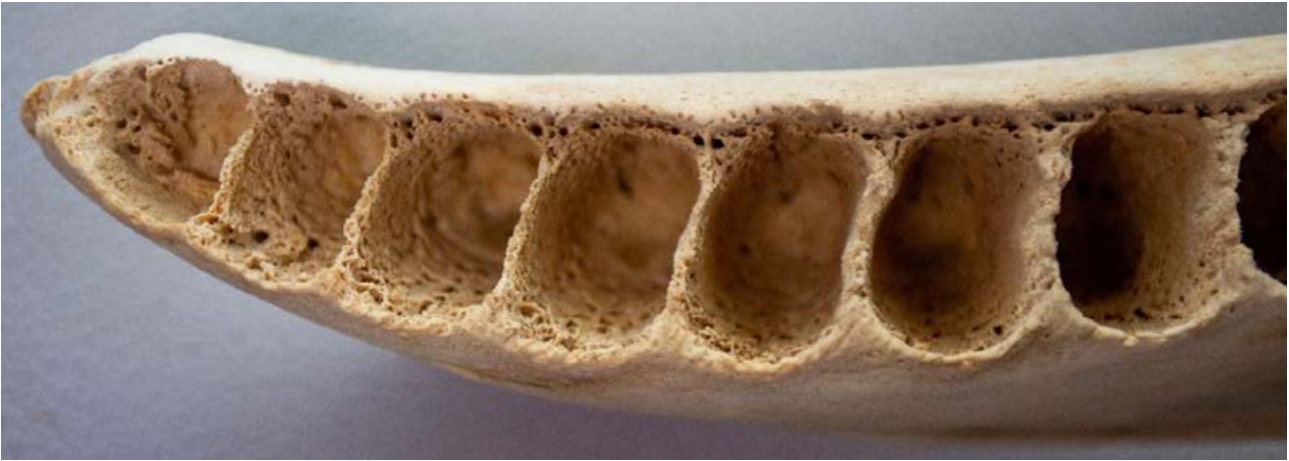


Figure 3. Mandible (lower left jaw, disarticulated), of an adult free-ranging female orca (525cm total body length), with the teeth removed, showing the alveoli for teeth 1-7. Photo: © Ingrid N. Visser.

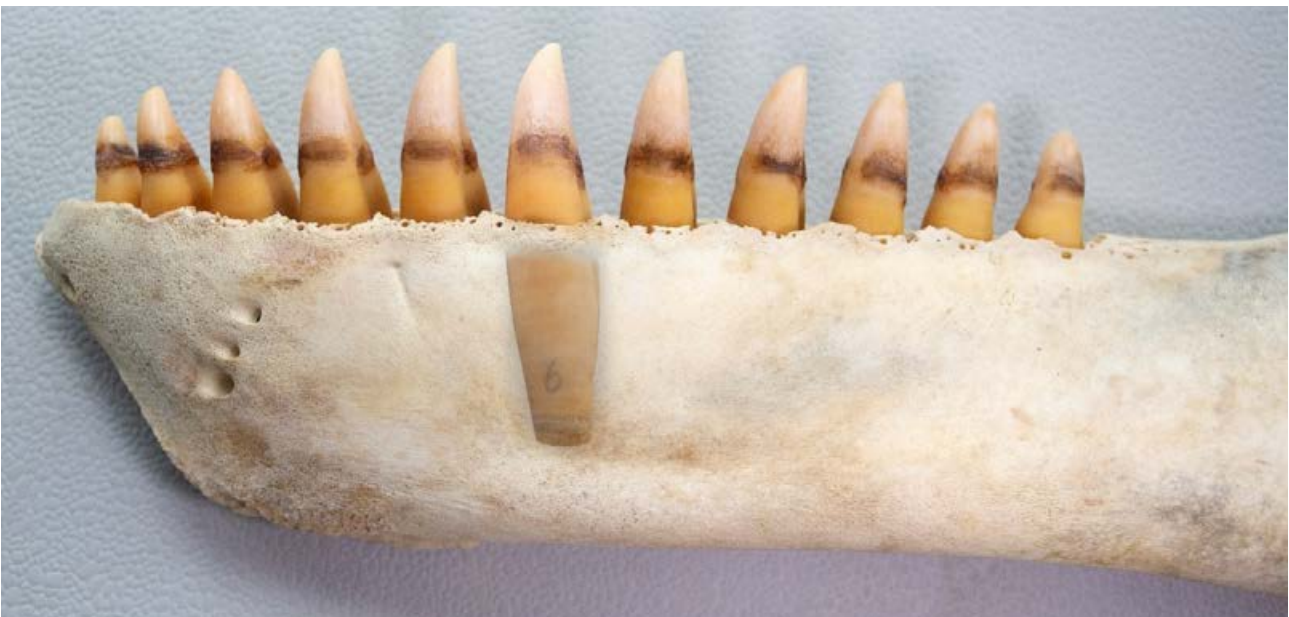


Figure 4. Lower left jaw (mandible, disarticulated) of an adult free-ranging female orca (525cm total body length), with the teeth in situ. One tooth (LL6) has been 'exposed' (using photo-editing software) to indicate the depth the tooth is imbedded into the mandible. Of note is that the gum would encompass the teeth up to the cingulum (at the zone of the 'dark line' which is created by plaque growth at the zone between the enamel and cementum - see Figure 5 for details). Note also the three foramens (holes) to the left of the mandible, where the mandibular nerves and blood vessels exit the bone to enervate and vascularise the tissue of the mandible (lips gums etc). Photo: © Ingrid N. Visser.

Within the mouth of an orca, the teeth vary in size; being larger in the middle of the jaw and descending in size both anteriorly and posteriorly. The largest tooth is usually number 5, 6, 7 or 8. Figure 6 shows the upper left (UL) and lower left (LL) teeth from an adult free-

ranging female orca (525cm total body length) from New Zealand waters, showing the variation in size of teeth. The UL had 13 teeth, with one being a vestigial (non-functioning) tooth (far left), compared to the LL jaw which had 11 teeth.

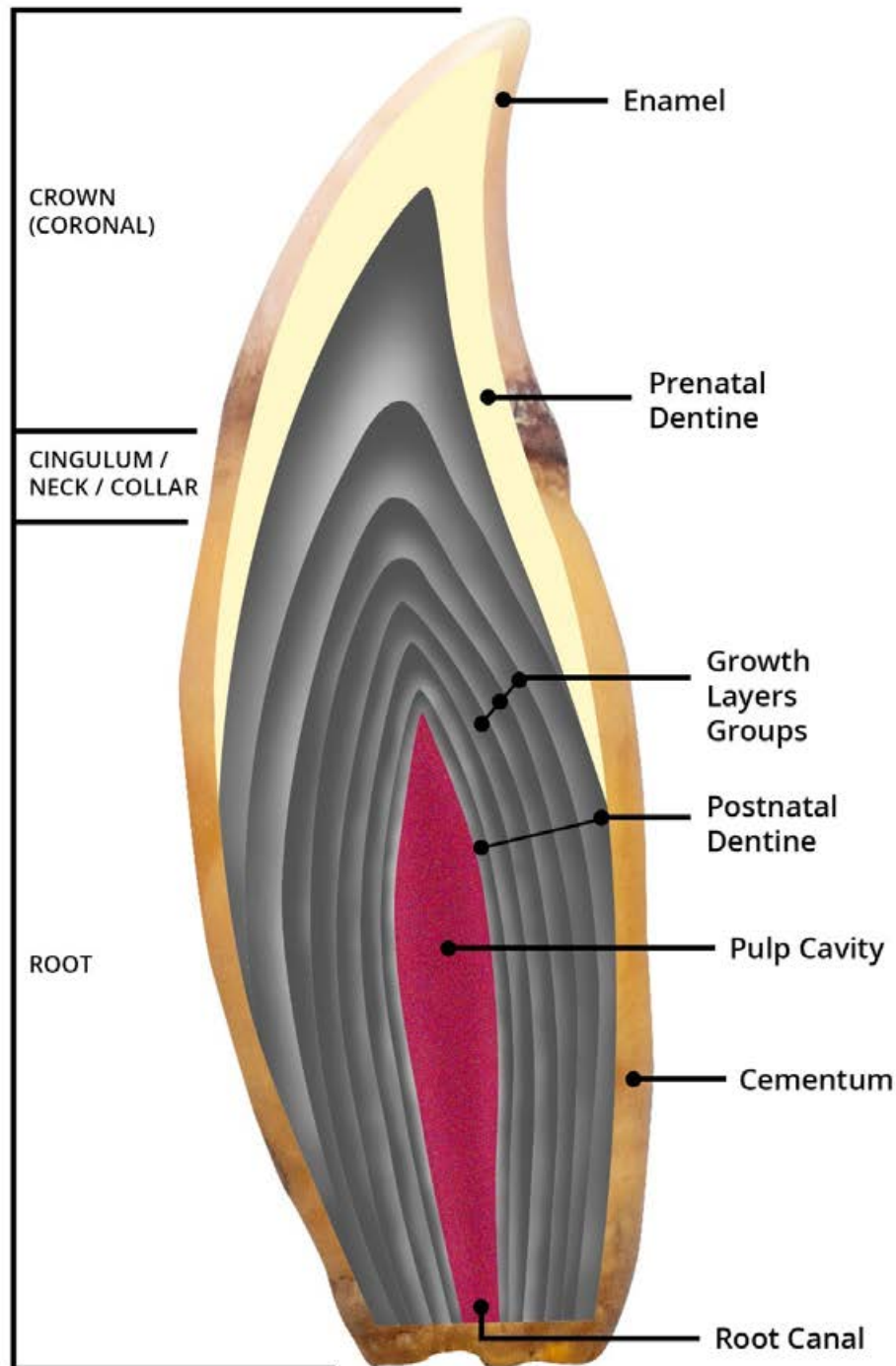


Figure 5. Graphical overlay onto an orca tooth, to illustrate the sections and terms. Schematic: © Orca Research Trust.



Figure 6. UL and LL teeth from an adult free-ranging female orca (525cm total body length) from New Zealand waters, showing the variation in size of teeth. Note the difference in colour between the coronal/cingulum/root sections of the teeth. The cingulum is the area where the gum surrounds the teeth. Photo: © Ingrid N. Visser.

As an orca ages, the cementum and dentine are deposited in 'growth layers' (Figures 5 & 7), with very young animals having a higher ratio of pulp and associated nerve tissue to the hard structure of the tooth compared to older orca. Figure 7 shows a tooth of a male captive orca (who died when he was 261 cm long and weighed 216 kg and was estimated to be less than two years old). In this case the tooth pulp encompassed more than 90% of the internal structure of the tooth. As an orca ages, the pulp area is reduced, due to the annual deposition of dentine in Growth Layer Groups, inwards, in a series of 'elongated nested cones' (Figures 5 & 7).

Jett et al. (2017) note the following regarding orca dentition;

"Unlike free-ranging orca which hunt live prey, orca in captive settings are fed exclusively a diet of dead fish, dead squid and gelatin (the latter administered to mitigate chronic dehydration). These food items are placed into the posterior region of the oral cavity by facility workers and the items are subsequently swallowed, with taking [sic] making minimal, if any, contact with the food. Despite the absence of contact with food items, captive orca teeth commonly exhibit

extensive wear and other dental pathologies such as fractures and exposed pulp cavities. In the United States of America (US), the severity and prevalence of dental pathology among captive orca has prompted animal welfare complaints to be filed in 2015 with the US Department of Agriculture's (USDA) Animal and Plant Health Inspection Service (APHIS), the agency charged with administering the Animal Welfare Act. Onsite USDA investigations of those orca, owned by a US-based theme park, confirmed poor dentition, which included exposed pulp cavities from severe dental wear."⁴

⁴ References within this passage omitted, see Jett J, Visser IN, Ventre J, Waltz J, Loch C. 2017. Tooth damage in captive orcas (*Orcinus orca*). *Archives of Oral Biology*. 84:151-160., for references and more details.

They further state; "Both the captive orca diet and feeding method [see Figure 11] are insufficient to dislodge food and other debris that accumulates in an exposed tooth cavity and this accumulation can become a locus for infection. In an effort to both treat active abscesses and prophylactically avoid infection and health complications, captive orca at theme parks often undergo a modified pulpotomy procedure. In this procedure,

staff core-drill diseased or threatened teeth, with the primary objectives of pus drainage, removal of diseased pulp tissue and clearing of impacted food and debris. However, contrasting the common dental protocol for humans and some other mammal dentistry, the bore holes in captive orca teeth are not typically sealed with amalgam or composite resins."⁴



Figure 7. Left. A half tooth and a whole tooth from a very young captive male orca (estimated to be less than 2 years old, as it was only 261 cm long and weighed 216 kg). The majority of the inner tooth would have been comprised of the nerve rich tooth pulp (now hollow). **Right.** A tooth of an orca of a wild male orca (8.81m total body length and 26 years of age, indicated by the black dots on each Growth Layer Group). In this case the pulp is less than 10% of the tooth. Photos: © Left Ingrid N. Visser; Right Perrin and Myrick (1980).

The teeth of orca have enamel (above the gum). In a previous study looking into how strong the dental tissues of dolphins are, orcas ranked as the second hardest enamel of 10 dolphin species tested (Figure 9).

Additionally, in comparison to humans, cattle and sharks, the mean hardness of orca teeth is harder than both cattle and sharks (Figure 10), and is surpassed only humans and one other dolphin species.

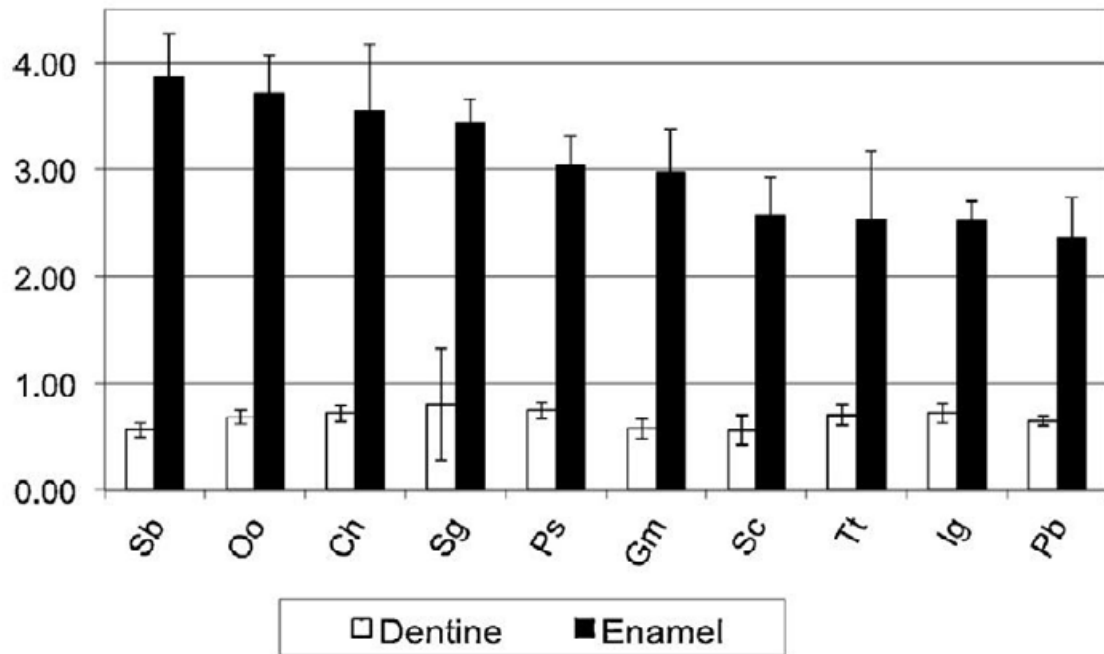


Figure 9. Mean hardness values in GPa±SD of teeth for 10 dolphin species (Oo indicates *Orcinus orca*), the second hardest of the dolphin species. Figure from Loch et al. (2013, Figure 3).

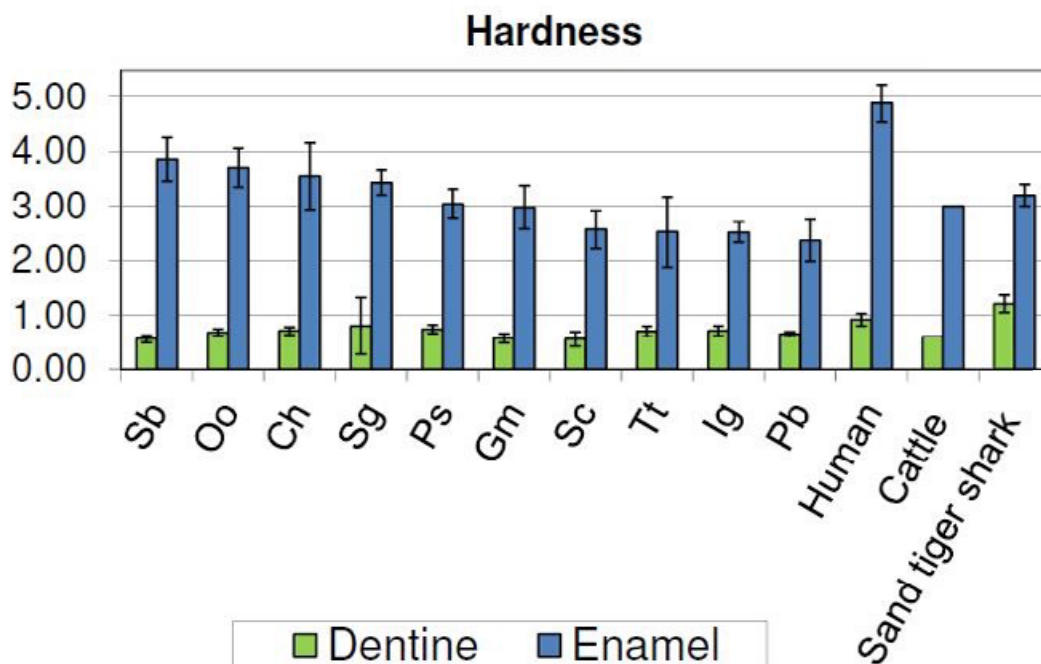


Figure 10. Mean hardness values in GPa±SD of teeth for 10 dolphin species in comparison to humans, cattle and sand tiger sharks (Oo indicates *Orcinus orca*). Figure from Loch et al. (2013; their Figure 3).




Figure 11. The typical feeding method for orca in captivity at facilities like Marineland Antibes has the facility worker tossing a handful of dead (previously frozen, now thawed) fish, which is dumped into the back of the mouth of a 'stationed' orca. The fish (and ice) do not touch the animal's teeth and the fish are so small that no food manipulation is required. This image is of Inouk in 2016. Note that all his teeth are worn down to, or below, the gums or they are completely missing. Photo: © Ingrid N. Visser

INOUK'S TOOTH DAMAGE:

Based on the methods described in the 2017 study, «Tooth damage in captive orcas (*Orcinus orca*)»⁵, we evaluated photographs and video of Inouk's mandibular (lower) and maxillary (upper) dentition (Figures 11 to 15 and see Appendix 2).

Each visible tooth was scored for coronal wear, wear at or below gum line and bore holes. Missing teeth were also noted and a dental pathology score calculated.

Inouk's raw dental pathology scores, as well as his age-adjusted dental pathology scores, rank him substantially worse than any of the 29 the captive orca comprising the 2017 study referenced above. Specifically, for both mandibular and maxillary teeth, Inouk's dental pathology scores were higher than all other captive orcas for apical wear, proportion of teeth worn at or below gumline, and the proportion of teeth possessing bore holes. All of his teeth (that we were able to obtain images of) are either

missing, or exhibit 'extreme' (> 75%) coronal tooth wear (Table 1 and see details listed in Figure 12).

More precisely, when considering combined pathology scores for both mandibular and maxillary teeth, Inouk's mean apical wear score (4.0) is higher than the next highest mean apical wear score for an evaluated captive orca (3.95); the proportion of his teeth worn to or below gumline (1.0) is higher than the captive orca with the next highest proportion of teeth worn to or below gumline (0.69); the proportion of his teeth with visible bore holes (0.63) is higher than the next highest proportion of teeth with bore holes (0.39); and the proportion of his teeth that are missing (0.41) is higher than the captive orca with the next highest proportion of missing teeth (0.20).

In summary, Inouk has chronic and extensive dental damage, ranking him as the worst of all captive orca evaluated using these methods to assess dental damage.

TEETH VISIBLE	MISSING / or NOT VISIBLE	EXTREME CORONAL WEAR	WORN TO THE GUM (or below)	BORE HOLES
LR 1-7	LR 8-12	LR 1-7	LR 1-7	LR 2-5 (poss. 6, 7)
LL 1-7	LL 8-11	LL 1-7	LL 1-7	LL 2-6 (poss. 7)
UR 2-7	UR 8-12	UR 2-7	UR 2-7	UR 4, 7
UL 2-7	UL 8-13	UL 2-7	UL 2-7	UL (poss. 6, 7)

Table 1. Summary of Inouk's teeth, as assessed using the criteria outlined in Jett et al. (2017).

We documented that between 2011 and 2016 there was a noticeable growth of the gums over some of the teeth (e.g., see LR2 & LR3 in Figures 13 and 14). We do not have any close-up photographs of these teeth post 2016 but have no reason to assume that this gum growth has not continued. Such gum overgrowth could present complications when flushing the teeth.

Documentation (Figure 12), from the facility holding Inouk, i.e., Marineland Antibes, confirms that his teeth

must be flushed at least twice a day ("Teeth in lower jaw are worn down due to biting the concrete walls. Pulp is exposed on LL#3/#4/#5 and LR #3/#4/#5. All teeth are drilled open and need to be flushed twice a day.")

Typically, flushing is done using hydrogen peroxide (Hargrove and Chua-Eoan 2015), bleach and/or iodopovidone (betadine).

⁵ Jett, J., I. N. Visser, J. Ventre, J. Waltz and C. Loch (2017). «Tooth damage in captive orcas (*Orcinus orca*). Archives of Oral Biology 84: 151-160.

Inouk:

Male.
Weight about 1900 kg.
Length 490 cm

Social background:

Born at Marineland 23/2/1999
Son of Sharkan, father is Kim.
Often not comfortable when he is alone in a pool (especially two pools away from Sharkan), poor control or breaking from control. Swimming with head-nods and vocal.
Dominated by all the other whales.

Medical:

Has a scar on the end of the dorsal done by Freya.
Often sick, due to aggressions of other animals or teeth infections.
Teeth in lower jaw are worn down due to biting the concrete walls. Pulp is exposed on LL #3/#4/#5 and LR #3/#4/#5. All teeth are drilled open and need to be flushed twice a day.
The pulp is removed on teeth LL #3 Because this teeth gave many infection problems.
All teeth don't have a normal shape. Inouk went through a period where his teeth were "peeling" a lot. The reason for this is not known but we think it is because of his regurgitation, the asset that comes up with the food could affect the teeth.
He regurgitates a lot but never had any major health problems because of it. (except for the teeth peeling)
Always hard to keep his food base high.
From time to time Candida problems on tongue, spots.

Reinforcement history:

He's much better with primary than he was but sometimes spit handful when not comfortable.
We avoid giving him blue marlin (due to the throat issue).
Does not like ice in his fish.

Aversive situations:

Some difficult sessions alone in a pool, he often splits to his mom's gate.
Being 2 pools away from mom.
Being alone.

Training history:

Is often very motivated to learn and maintains attention in longer or difficult situations.
Good target basics, attentive to whistle bridge, hand slaps and recalls in most situations.
Can have very low energy level.

Water work:

Did water work alone and also double water work (with 1 or 2 trainers) with Sharkan, Freya, shouka, Wikie and val.
Has a history with pinning trainers against the wall.
When training water work, often had a tail-slap next to, or on the trainer after a recall.
Has grabbed socks, legs during water work. Has been very mouthy.

Aggressive tendencies:

Has tried, sometimes, to reach for a trainer on deck after an incorrect behaviour or when hyper.
Could be mouthy when trainers were doing mouth check-up...
Has opened his mouth on minimal occasions toward a trainer in the water but responded appropriately to control following this display.

General/current:

Tried to lowering his pilucalm (15/3/2008) When he was at 1.5 tbl. he almost stop eating and split a lot in sessions. Not able to do teeth anymore so he went back to 6 tbl. pilucalm.
September 2009 started to lower Pilucalm again much slower then we did in 2008. He is at 1.25 tbl. now (Jan 2010) and doing great still eating really good.

Figure 12. Animal profile of Inouk the captive male orca. Prepared by Marineland Antibes prior to February 2010 (see last two lines "now (Jan 2010)"). Supplied to Orca Research Trust via Orca Aware.

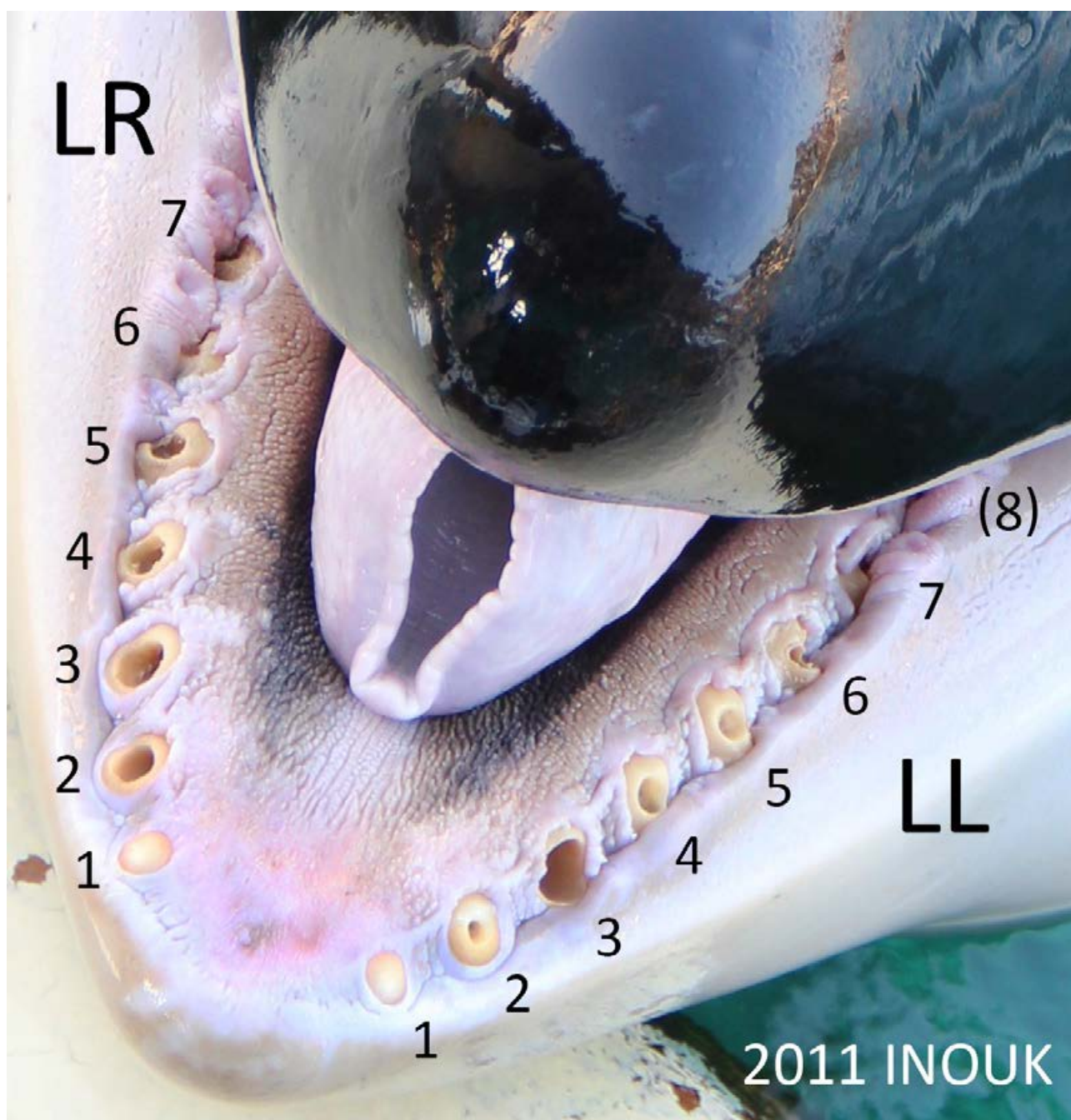


Figure 13. Inouk's mandibular teeth in 2011. Only LR1 and LL1 of his visible teeth are not drilled (although in teeth LR6, LR7 and LL7 the bore holes are not fully visible). Tooth LL6 appears to be broken and tooth LL(8) is missing or is overgrown by gum (as indicated by the tooth number being in brackets). Photo: supplied to Orca Research Trust via Orca Aware.




Figure 14. Inouk's mandibular teeth in 2016. Only LR1 of his visible teeth is not drilled. It is unclear if teeth LR(7) is now missing or is overgrown by gum or hidden by the mandibular tissue (compare to LR6 & LR7 in 2011, Figure 13 and see Figure 15, where tooth LR6 is visible). Numbers in brackets indicate teeth that are missing or are overgrown by gum (or in this case hidden by the mandibular tissue). The alveoli for teeth LL(6) to (11) are indicated by raised/protruding gum/epithelial tissue, but again it is unclear if teeth are covered over or are missing. Photo: © Ingrid N. Visser.

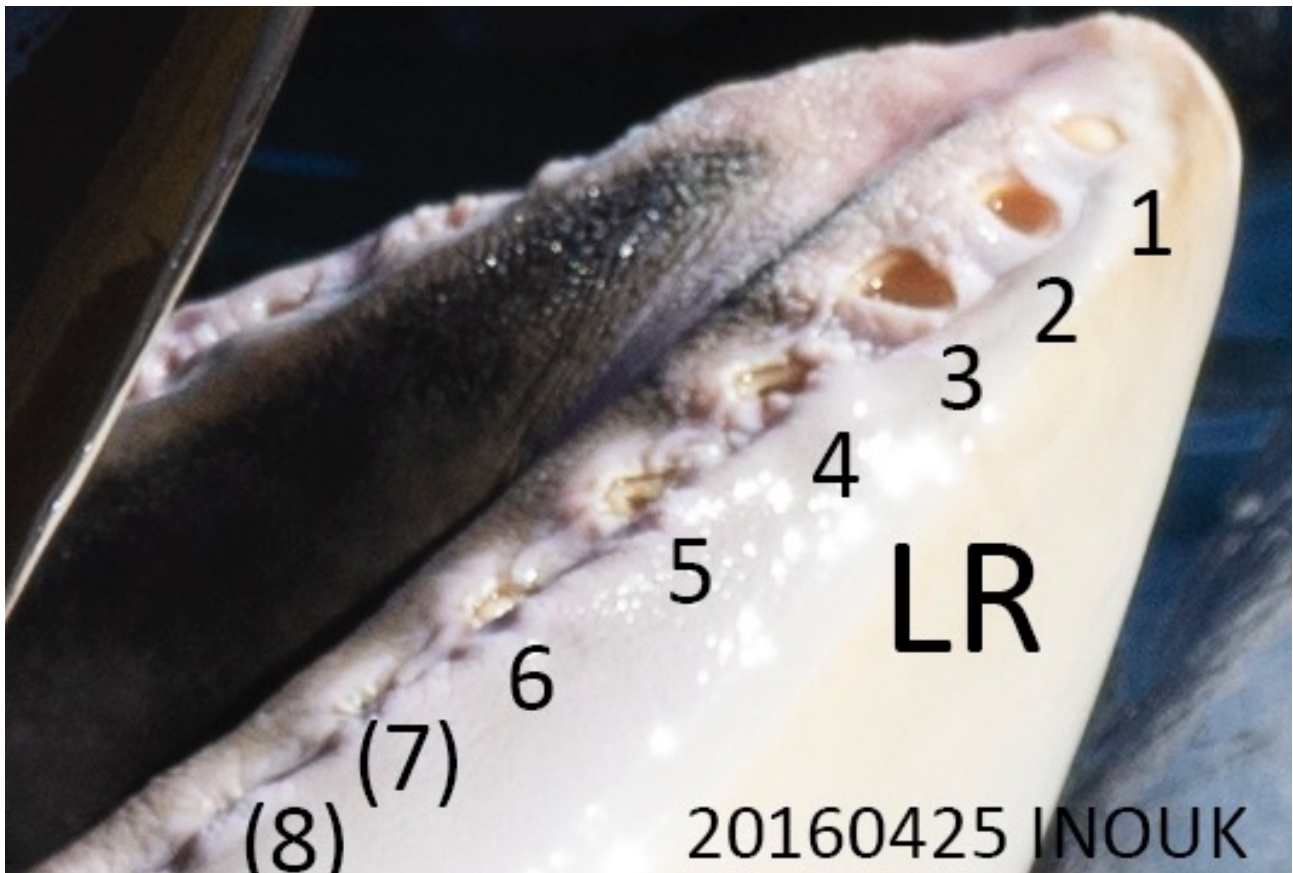


Figure 15 . Inouk's teeth on same day as Figure 14, showing tooth LR6 (partially visible). Photo: © Ingrid N. Visser

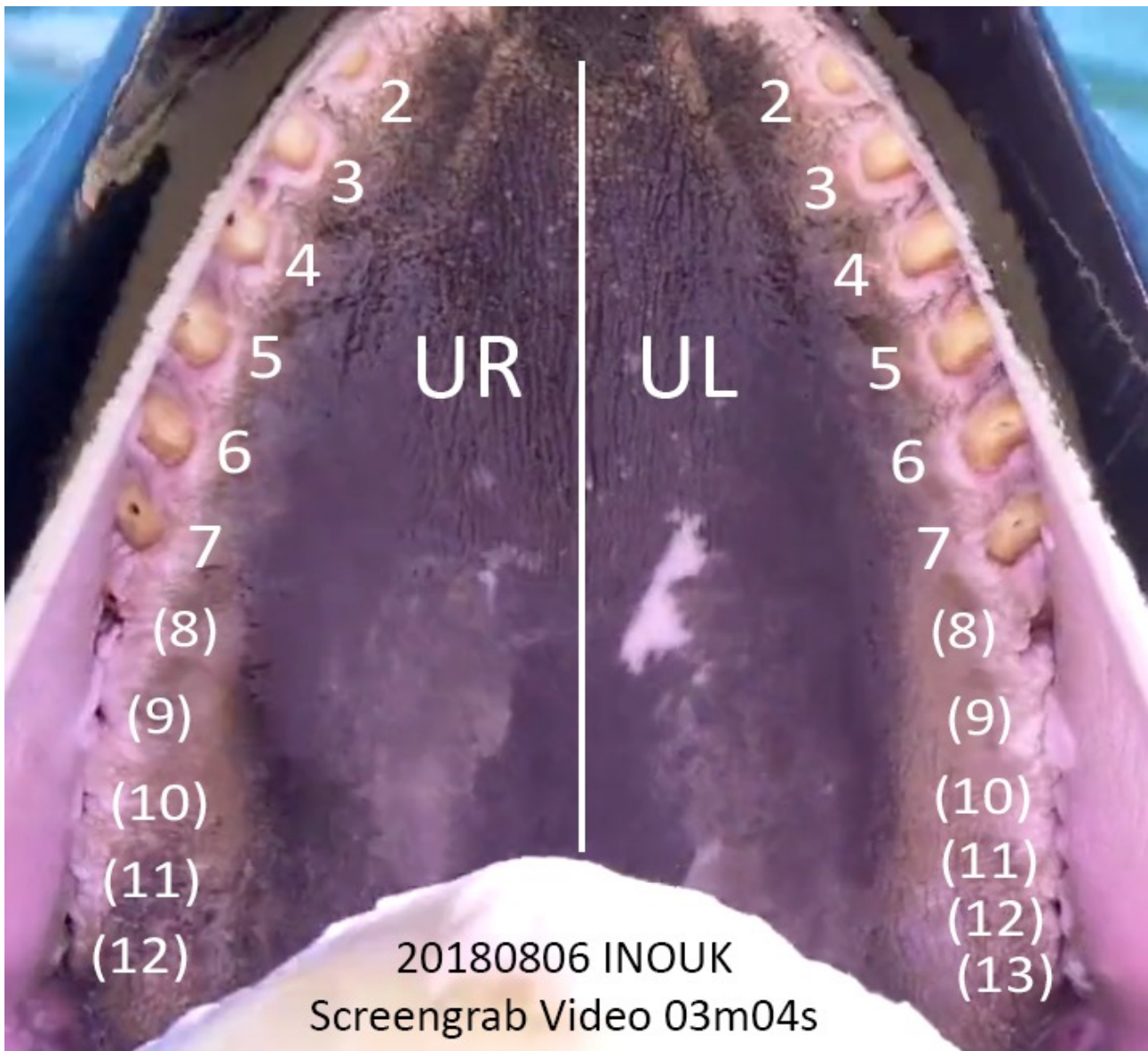


Figure 16. Inouk's maxillae teeth in 2018. Teeth UR1 and UL1 are not visible in this image taken from a video, it is therefore not possible to ascertain the amount of damage they have sustained. However, all other visible teeth are worn to the gums (i.e., 'extreme' wear with more than 75% of the coronal section of the tooth worn away). Teeth UR5 and UR7 appear to have been drilled, whilst UL6 and UL7 appear to either have initial tooth pulp exposure or small-bore holes drilled. Numbers in brackets indicate teeth that are missing or are overgrown by gum. Photo: extracted from video supplied to authors.

INOUKS COMPROMISED HEALTH:

Prior to February 2010, Marineland Antibes had prepared an assessment of Inouk (Figure 12), in which serious health and behavioural issues that he was facing at the time were clearly identified. It is likely that Inouk continues to face these or similar issues today. The aspects Marineland Antibes identified included stereotypies (abnormal, repetitive behaviour) such as “biting the concrete walls” and “regurgitation”. Biting concrete walls has been identified as a major cause of wear on captive orca teeth (Graham and Dow 1990; Visser and Lisker 2016). Additionally, rubbing, chewing or biting on other hard surfaces such as toys can result in damage to teeth.

Aggression (between orca) can also result in damage to teeth – including through ‘jaw popping’ (Ventre and Jett 2015) and the fast closing of teeth, which normally interdigitate (see Figure 17). Inouk is noted by Marineland Antibes as “dominated by all the other whales” (see Figure 12), which may mean that when he is ‘protected’ from the other orca, by a gate, he may display aggressive tendencies such as jaw popping. In addition, in captive environments where spatial escape is not possible, subdominant animals experience chronic stress, which can lead to oral stereotypies and other pathologies (Azpiroz et al. 2003).

One sign of stress in captive animals is regurgitation (Akers and Schildkraut 1985; Baker 1997). It is well recognised in humans as a contributor to tooth erosion (Kelleher and Bishop 1999). Marineland Antibes wrote in 2010 that “Inouk went through a period where his teeth were “peeling” a lot. The reason for this is not known but we think it is because of his regurgitation, the asset [sic: acid] that comes up with the food could affect the teeth. He regurgitates a lot ...”.

Regurgitation has recently been linked to a range of stress-related behaviours and environmental conditions, by a veterinarian and other staff at SeaWorld (another facility which holds orca and other cetaceans). They stated; “Regurgitation may be the result of behavioral abnormalities ... Juvenile onset regurgitation may be seen in young cetaceans related to boredom, illness, decrease in a previous level of interaction, social instability, lack of adaption to training techniques, misinterpreting fish as a play item, etc.” (Walsh et al. 2016). Although the Marineland report fails to document when Inouk first began regurgitating (Figure 12), it is clear that the behaviour has been ongoing since 2010 when he was 11 years old (i.e., not yet sexually mature and therefore could be considered a juvenile).

Regarding cetacean regurgitation, SeaWorld staff elaborate further by stating that “Some individuals may exhibit this behavior for short periods with self-termination while others may progress in frequency, duration, and severity to the exclusion of normal activity. A medical workup should be performed when the

behavior is persistent, ... In addition to complete blood counts, serum chemistries, gastric and fecal cultures and cytology, and body weight, the subject should undergo gastroscopy to evaluate for ulceration, gastritis, or foreign body.”

The severe nature of regurgitation is emphasised by Walsh et al. (2016) when they note that if regurgitation is “Allowed to persist the condition can lead to severe weight loss, immune system compromise, increased susceptibility to disease, and death.” In order to document the situation, Walsh et al. (2016) state that “Individuals should be closely monitored with serial weight determination to pick up early signs of deterioration. A complete behavioral evaluation should be conducted including a review of past relationships with peers and personnel, changes in training interaction, environment, and social structure. Often the animals are considered «loners», incompatible, placed outside the normal social structure by age or lack of suitable peers.” These latter points are certainly the case with Inouk as there are notes in his profile compiled by Marineland Antibes that state that he is incompatible with the other orca (he is “dominated by all the other whales”, which includes animals much younger than him). He has no social peers by age or social standing, at Marineland Antibes.

But the SeaWorld staff also note that the problem with regurgitation poses other serious health risks for cetaceans; “Individuals which continue to deteriorate may develop secondary problems with yeast infections or clostridial overgrowth so periodic medical exams should be performed. Treatment is geared to a number of additional concerns. Chronic regurgitation may lead to esophageal ulceration.” Recalling that Marineland Antibes wrote that “We avoid giving him blue marlin (due to the throat issue)” and that Inouk has been infected “From time to time [with] Candida” (a yeast infection), it is clear that Inouk has suffered due to his regurgitation.

The SeaWorld veterinarian Walsh and co-authors write “Relocation, separation from inappropriate social structures and a reevaluation of human interaction may be required... It is rare to totally eliminate regurgitation in extreme cases, but the goal is reduce the incidence and eliminate medical complications. Personnel must be educated to the chronic nature of this disorder and be aware of the visual cues of weight loss and the potential for recurrence.”

Oddly, Marineland Antibes states “... but [Inouk] never had any major health problems because of it [regurgitation]. (except for the teeth peeling). Always hard to keep his food base high.” – Based on our direct experience working with cetaceans and familiarity with medical records in both captive and rehabilitation environments, it is known that difficulties in feeding (i.e., as described by Marineland Antibes.), are often indicative of fundamental health or social issues (such

as pain, disease, infection, social strife, stress etc.). As a result of a poor-health baseline, behaviour can include reduced activity, low energy levels, 'picky' eating habits and aggression (to orca or humans).

It therefore comes as no surprise to read that Marineland Antibes has included the comments about Inouk that reflect a poor-health baseline such as illness and infections; "often sick, due to aggressions of other animals [orca] or teeth infections", "this teeth [sic: tooth] gave many infection problems", "throat issue", "from time to time Candida problems on tongue, spots".

These observations fit with Medway's (1980) publication (i.e., nearly 30 years ago) that the fungal disease Candida may also be impacting his oesophagus (throat); "Candidiasis is a yeast-environment problem that has been plaguing aquaria where cetaceans [whales, dolphins and porpoise] are kept for a number of years. The disease may be generalized, but it is manifested mainly by lesions around and associated with mucocutaneous junctions, eg, blowhole and vagina. Ulceration of the esophagus is believed to be pathognomonic for candidiasis. The cause (Candida albicans) is a simple yeastlike fungus."

Medway also notes that the "... disease is related to or associated usually with overuse of antibiotics, overtreatment of water for purity, or both." and goes on to state "Recently, it has been shown that Candida flourishes in cetaceans that are immunosuppressed for unknown reasons. ... The presence of other conditions, resulting in debilitation of the animal and the flourishing of Candida or other organisms, should not be overlooked."

This is reinforced by the respected encyclopaedia of veterinary medicine 'Merck Manual' (Aiello and Moses 2016), which states «Captive marine mammals seem particularly prone to fungal infections,» the manual also states «This common mycotic disease [Candida] in captive cetaceans occurs secondary to stress, unbalanced water disinfection with chlorines, or indiscriminate antibiotic therapy.» Furthermore, Candida has been implicated in the death of a number of captive orca (Kielty 2011; Schelling 2015). Along these lines, it is known that captive orcas are often, sometimes chronically, administered antibiotics due to a variety of captivity-related pathologies including dental damage (Jett and Ventre 2012).

The Marineland Antibes document also states that Inouk "can have very low energy level", and that he "does not like ice in his fish" and again these may be signs that he is suffering ill health. A thorough investigation of Inouk's medical records are warranted to better understand the extent of the issues.

With regards to aggression towards trainers, Inouk "has a history of pinning trainers against the wall", "often had a tail-slap next to, or on the trainer...", "has grabbed socks [soft wetsuit shoes on feet of trainers], legs during water work", "has been very mouthy", "... reach for a trainer on deck..." and "opened his mouth on minimal occasions toward a trainer in the water...". Although Inouk has no intact teeth left due to captivity, he still weighs in excess of 1,900 kg and could easily kill a worker (as other orca have done in captivity, see Parsons 2012).

Furthermore, with all the dental damage that Inouk has, it is likely that he is in constant pain. Veterinarian Dentist specialist Dr Faracas (DMV, DAVDC) writes about oral pain in animals; "The oral cavity of animals is innervated ("wired") by the same type of nerves in dogs and cats as in humans. These nerves collect information, including information about harmful or painful stimuli, and allow for quick, reflex responses as well as carry this information on to other parts of the brain. This sharp perception of pain is an effective warning and protective mechanism in animals and humans alike. The same nerves also inform the brain when structural damage to the oral cavity occurs. Oral pain is proportional to the severity and extent of the problem. In cases where the problem and associated pain is significant, impairment or loss of function occurs."

Despite the fact that there are no differences in how humans and animals experience oral pain, when it comes to voluntary display of oral pain, only humans are willing to let others know that they are in pain.

In nature, oral pain is a liability for the individual and the group to which [it] belongs. In animals, displaying oral pain may trigger retaliatory, competitive, or predatory behavior from others."⁶

⁶ <https://www.animaldentalclinic.com/oral-health/>



Figure 17. A life-size museum replica orca skull and teeth, showing interlocking homodont dentition. Photo: © Ingrid N. Visser

It is not clear if Inouk is receiving any pain or other medications for his exposed dental pulp, as the profile compiled by Marineland provides limited detail. However, their one page document (Figure 12) does list that Inouk is receiving 'Pilucalm' – a progestin drug (synthetic sex and steroid hormone) used in humans for palliative treatment of advanced cancer treatments (for uterine and breast cancer), for the treatment of unexplained, significant weight loss in patients with a diagnosis of acquired immunodeficiency syndrome (AIDS) antineoplastic and it is also listed as an appetite stimulant⁷. It is likely that the drug is used as an appetite stimulant for Inouk as the Marineland assessment document states "Tried to lowering [sic] his pilucalm (15/3/2008) When he was at 1.5 tbl. He almost stop [sic] eating and split a lot in sessions. Not able to do teeth anymore so he went back to 6 tbl. Pilucalm. September 2009 started to lower Pilucalm again much slower then [sic] we did in 2008. He is at 1.25 tbl. Now (Jan 2010) and doing great still eating really good."

It should also be noted that Inouk has a collapsed dorsal fin (Figure 18), which has been documented in free-ranging orca as associated with poor health and trauma (Visser 1998; Matkin et al. 2008; Durban et al. 2009). Collapsed dorsal fins occur in less than 1% of free-ranging adult male orca, whilst in captivity 100% of adult male orca have this disfigurement. Dorsal fin collapse in captivity is due to complex interactions of multiple factors (Figure 19). For example, captive orca who spend

inordinate amounts of time logging at the surface of the water may expose their dorsal fins to sun and high ambient temperatures. As such the collagen comprising their dorsal fin may denature and the fin eventually collapses.

Based on the evidence gathered and presented here, it is our opinion that Inouk has suffered due to his extensive and dramatic dental damage. The damage includes but is not limited to the issues indicated in the Figures presented herein. The manner in which these all potentially interact is illustrated in the 'web' shown in Figure 19. In summary, Inouk suffered, and likely continues to suffer, from tooth loss, tooth fracturing and from teeth with exposed pulp. Inouk likely suffers from acute and chronic stressors associated with unnatural confinement. In effect, he has a reduced quality of life due to captivity.

⁷ <https://www.ndrugs.com/?s=pilucalm&t=dosage>



Figure 18. A cropped in image from video taken in 2018, showing the collapse of Inouk's dorsal fin, onto his right side. Note the open wound on the trailing edge (arrow). The other notches along the trailing edge are indicative of earlier wounds. Photo: extracted from video supplied to authors.

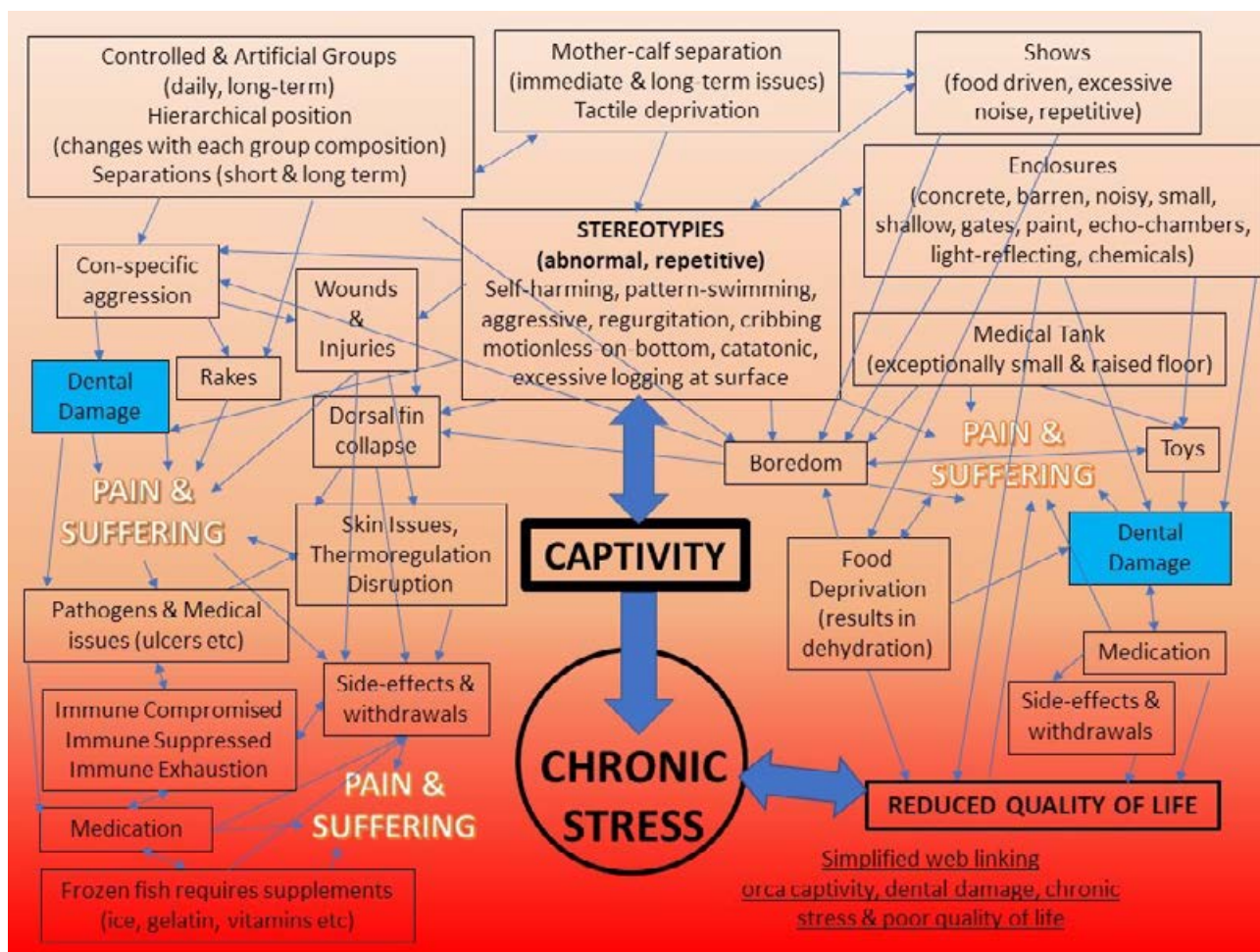


Figure 19. A simplified web linking orca captivity, dental damage, chronic stress and poor quality of life to pain and suffering. Schematic: © Ingrid N. Visser

Report compiled by:

Ingrid N. Visser (PhD)

Dr John Jett (PhD)

Dr Jeff Jett (MD)

Orca Research Trust
www.orcaresearch.org

REFERENCES

- Aiello SE, Moses MA, editors. 2016. The Merck Veterinary Manual. 11th ed. London, United Kingdom: Elsevier Health Sciences.
- Akers JS, Schildkraut DS. 1985. Regurgitation/reingestion and cropophagy in captive Gorillas. *Zoo Biology*. 4:99-109.
- Azpiroz A, Garmendia L, Fano E, Sanchez-Martin JR. 2003. Relations between aggressive behavior, immune activity, and disease susceptibility. *Aggression and violent behavior*. 8(4):433-453.
- Baker KC. 1997. Straw and forage material ameliorate abnormal behaviors in adult chimpanzees. *Zoo Biology*. 16:225-236.
- Dahlheim ME, Heyning JE. 1999. Chapter 11, Killer whale *Orcinus orca* (Linnaeus, 1758). In: Ridgway SH, Harrison RJ, editors. *Handbook of Marine Mammals*. London: Academic Press; p. 281-322.
- Durban JW, Fearnbach H, Ellifrit D, Balcomb KC. 2009. Size and body condition of Southern Resident killer whales. Contract report to the Northwest Regional Office, National Marine Fisheries Service, Order number AB133F08SE4742, Requisition Number NFFP5000-8-43300.
- Eschricht DF. 1866. On the species of the genus *Orca* inhabiting the northern seas. In: Flower WH, editor. *Recent memoirs on the Cetacea*. London: Ray Society; p. 153-188.
- Ford JKB. 2009. Killer whale. *Orcinus orca*. In: Perrin WF, Würsig B, Thewissen JGM, editors. *Encyclopedia of marine mammals*. San Diego: Academic Press; p. 650-657.
- Glass BP. 1974. A key to skulls of North American mammals. Stillwater: Oklahoma State University.
- Graham MS, Dow PR. 1990. Dental care for a captive killer whale, *Orcinus orca*. *Zoo Biology*. 9(4):325-330.
- Hargrove J, Chua-Eoan H. 2015. *Beneath the Surface: Killer whales, Seaworld, and the truth beyond Blackfish*. St Martin's Press.
- Heyning JE, Dahlheim ME. 1988. *Orcinus orca*. *Mammalian Species*. 304:1-9.
- Jett J, Ventre JM. 2012. Orca (*Orcinus orca*) captivity and vulnerability to mosquito-transmitted viruses. *Journal of Marine Animals and Their Ecology*. 5(2):9-16.
- Jett J, Visser IN, Ventre J, Waltz J, Loch C. 2017. Tooth damage in captive orcas (*Orcinus orca*). *Archives of Oral Biology*. 84:151-160.
- Kelleher M, Bishop K. 1999. Tooth surface loss: an overview. *British Dental Journal*. 186(2):61-66.
- Kertesz P. 1993. A colour atlas of veterinary dentistry and oral surgery London, England: Wolfe Publishing.
- Kielty J. 2011. Marine Mammal Inventory Report (Deficiencies). St Pete Beach, Florida, USA: The Orca Project Corp (unpublished report, available from <https://theorcaproject.wordpress.com/2011/03/18/noaa-nmfs-marine-mammal-inventory-report-deficiencies/>). Unpublished report No.
- Loch C, Swain MV, van Vuuren LJ, Kieser JA, Fordyce RE. 2013. Mechanical properties of dental tissues in dolphins (Cetacea: Delphinoidea and Inioidea). *Archives of Oral Biology*. 58(7):773-779.
- Matkin CO, Saulitis EL, Ellis GM, Olesiuk PF, Rice SD. 2008. Ongoing population-level impacts on killer whales *Orcinus orca* following the 'Exxon Valdez' oil spill in Prince William Sound, Alaska. *Marine Ecology Progress Series*. 356:269-281.
- Medway W. 1980. Some bacterial and mycotic diseases of marine mammals. *Journal of American Veterinary Medical Association*. 177(8):831-834.
- Nishiwaki M. 1972. General Biology. In: Ridgway SH, editor. *Mammals of the Sea: Biology and Medicine*. Springfield, Illinois: Charles C Thomas; p. 3-204.
- Parsons ECM. 2012. Killer whale killers. *Tourism in Marine Environments*. 8(3):153-160.
- Perrin WF, Myrick AF, editors. 1980. Age Determination of Toothed Whales and Sirenians. . Vol. Special Issue 3. Reports of the International Whaling Commission.
- Scammon CM. 1874. The marine mammals of the Northwestern coast of North America, together with an account of the American whale-fishery. New York: G. P. Putnam's Sons.

Schelling A. 2015 Orca dies at SeaWorld after spending her life in a tank. The Dodo, 22 Dec 2015 (available from <https://www.thedodocom/seaworld-orca-unna-dead-1520796874.html>). <https://www.thedodo.com/seaworld-orca-unna-dead-1520796874.html>.

Ventre J, Jett J. 2015. Chapter 8, Killer whales, theme parks and controversy: An exploration of the evidence. In: Markwell K, editor. Animals and tourism Understanding diverse relationships. 1st ed. UK: Channel View Publications; p. 128-145.

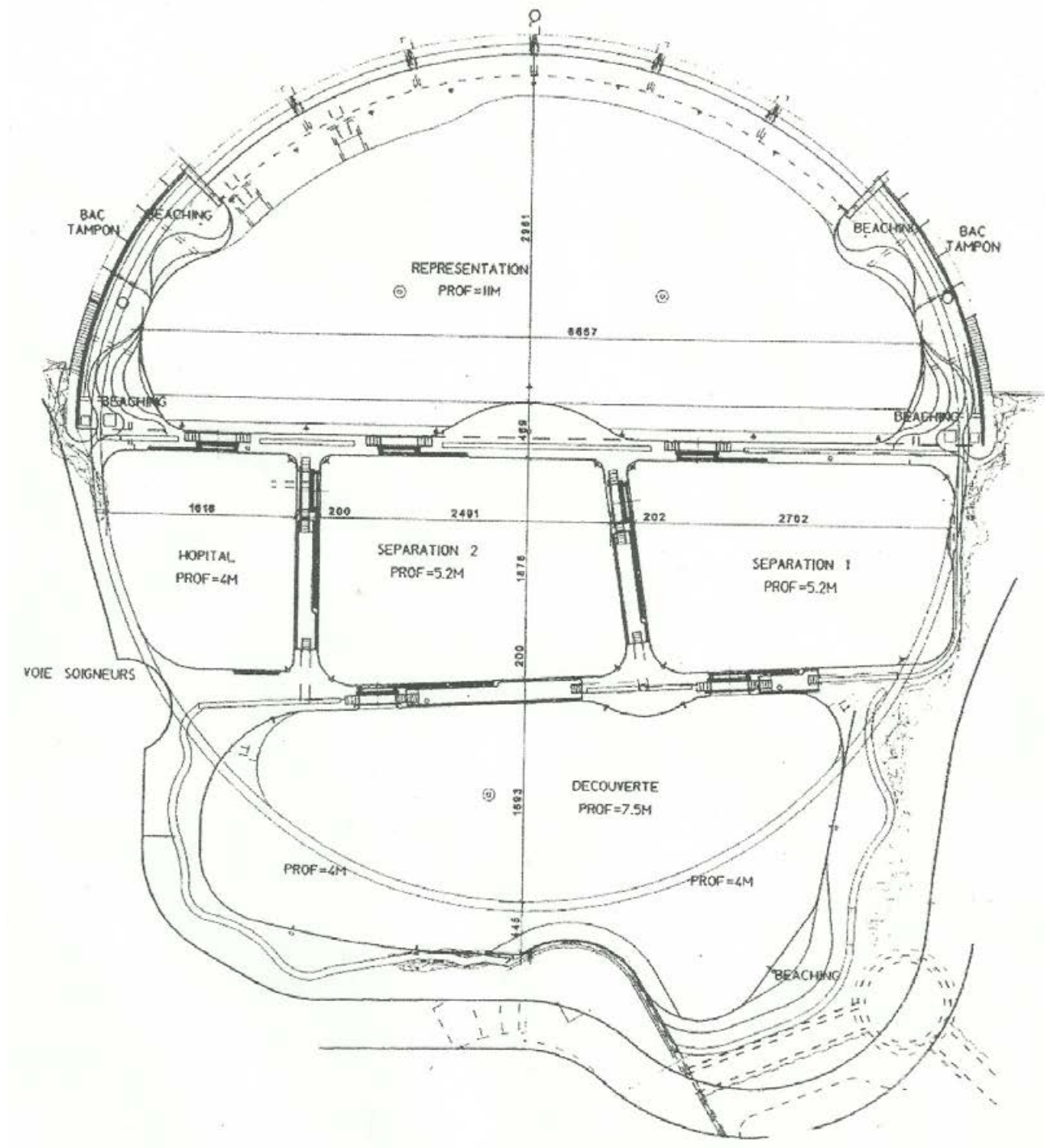
Visser IN. 1998. Prolific body scars and collapsing dorsal fins on killer whales (*Orcinus orca*) in New Zealand waters. Aquatic Mammals. 24(2):71-81.

Visser IN, Lisker RB. 2016. Ongoing concerns regarding the SeaWorld orca held at Loro Parque, Tenerife, Spain. Free Morgan Foundation.

Walsh MT, Friday RB, Johnson AB, Messinger D. 2016. Regurgitation in cetaceans: Medical implications. IAAAM 47th Conference of the International Association for Aquatic Animal Medicine May 21–26, 2016 Hosted by Virginia Aquarium & Marine Science Center, Virginia Beach, Virginia, USA.

APPENDIX I

Schematic layout of orca tanks at Marineland Antibes, France. Supplied to Orca Research Trust via Orca Aware



APPENDIX II

Images of Inouk (in addition to those presented in the main body of the report)

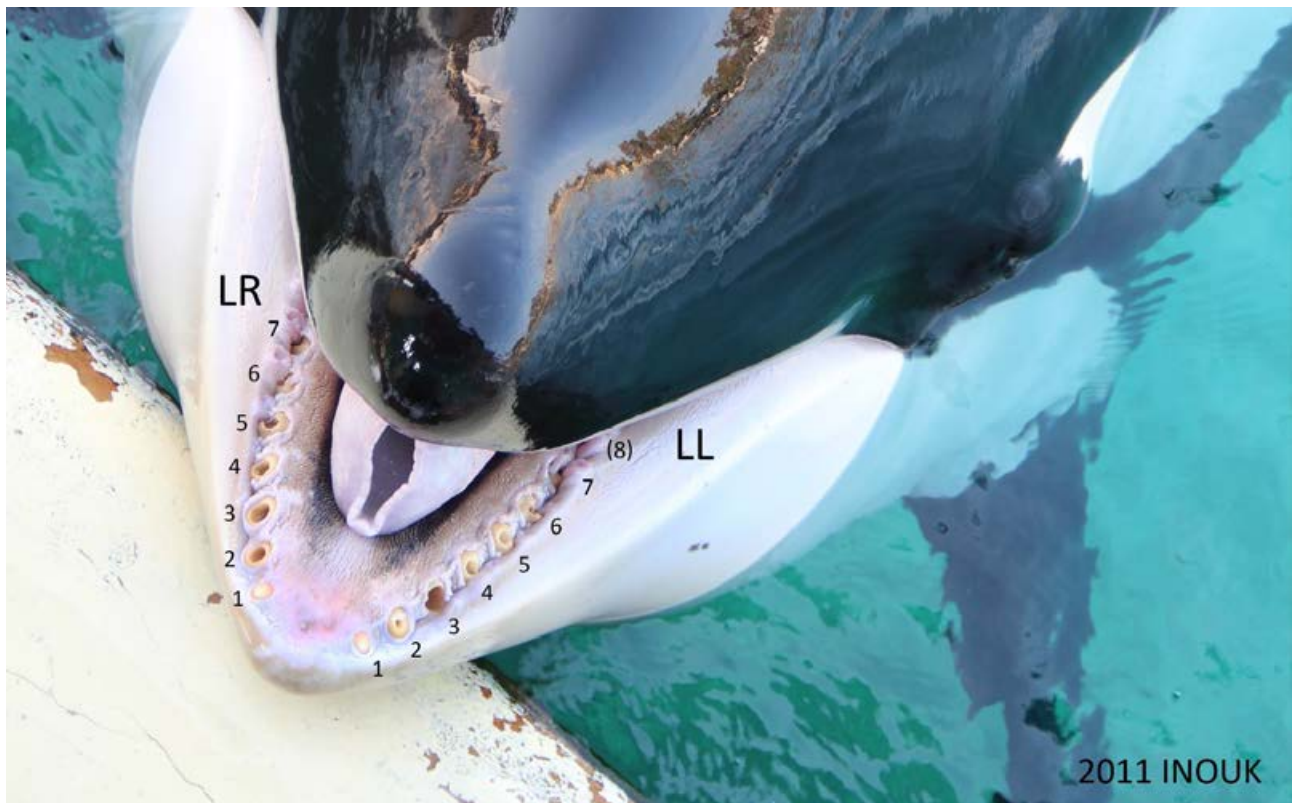

Figure A. Inouk in 2011.



Figure B. Inouk in 2016.



Figure C. Inouk in 2016.



Figure D. Inouk in 2016.



Figure E. Inouk in 2016.



Figure F. Inouk in 2016.



Our reports, including investigations
and scientific expertises are available on
www.one-voice.fr

 **NON** subventionnée
LIBERTÉ de parole garantie !



Head office

BP 41 - 67065 Strasbourg Cedex
Tél : 03 88 35 67 30

Administrative and missions department

7 place de la République - CS 20263 - 56007 Vannes Cedex
Tél : 02 97 13 11 10
info@one-voice.fr **www.one-voice.fr**